





**PATIENT**

Sairse Leijon

**SPECIES**

Canine

**BREED**

Rat Terrier

**SEX**

Female Spayed

**AGE**

11 years

**WEIGHT**

11lbs

**INTERPRETED BY**

Maggie Machen Lamy,  
DVM, DACVIM  
(Cardiology)

**IMAGING PERFORMED BY**

Loetitia St-Jacques,  
LVT/RVT

**HOSPITAL NAME**

Incline Veterinary  
Hospital

**REFERRING VET**

Dr. Moger

**INVOICE**

22963

**DATE**

3/7/22

**INTERPRETATION OF THE FINDINGS & FURTHER RECOMMENDATIONS**

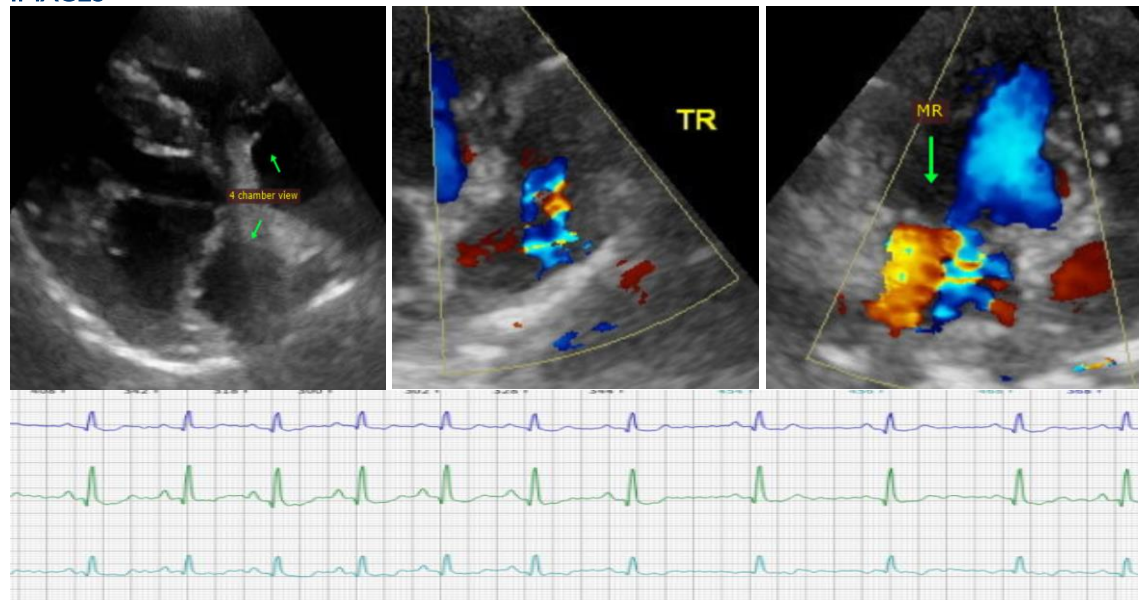
Chronic degenerative valve disease causing mild mitral and tricuspid regurgitation. Lack of significant left atrial enlargement indicates the current risk for complication is low. Early pulmonary hypertension is noted which is of unknown significance in an asymptomatic dog. No additional issues are noted in this study. The ECG is unremarkable with a respiratory sinus arrhythmia.

In an asymptomatic dog with no significant left atrial enlargement, no cardiac medications are clearly indicated. Assessment of progression in the future will help predict long term prognosis, which is highly variable at this stage. Omega fatty acid supplementation and mild salt restriction may be of some long-term benefit. Monitor for development of a cough, labored breathing, exercise intolerance or collapse episodes.

Anesthetic risk is considered mild if needed. Cardiac protective drug choices (opioid/benzodiazepine premedication, propofol or alfaxalone induction, isoflurane gas) are recommended. Pre-oxygenate for 5-10 minutes prior to induction. Monitor for arrhythmias, hypotension, and hypoxia both intra and post-operatively and intervene as necessary. Mild IV fluid restriction is recommended to avoid fluid overload. Avoid heart rate stimulating drugs such as atropine unless clinically indicated.

Recommend conservative monitoring with a recheck echocardiogram in 6 months, sooner if any development of clinical signs.

**IMAGES**





Portable Animal Western Sonography, Inc.

IMAGING PERFORMED BY

pawsonography@gmail.com  530-786-8340

**PATIENT**

Saoirse Leijon

The information and recommendations provided are based on the images presented by the referring veterinarian. No evaluation can be communicated regarding pathology that was not visible in the image/video clips provided.

**SPECIES**

Canine

Thank you for this referral. This report was generated using transcription software, and minor dictation errors may be present. If the clinical or image interpretation does not parallel your findings or if I can be of any further assistance, please contact me.

**BREED**

Rat Terrier

Maggie Machen Lamy, DVM  
Diplomate of the American College of Veterinary Internal Medicine (Cardiology)  
info@sonopath.com

**SEX**

Female Spayed

**AGE**

11 years

**WEIGHT**

11lbs

**INTERPRETED BY**

Maggie Machen Lamy,  
DVM, DACVIM  
(Cardiology)

**IMAGING PERFORMED BY**

Loetitia St-Jacques,  
LVT/RVT

**HOSPITAL NAME**

Incline Veterinary  
Hospital

**REFERRING VET**

Dr. Moger

**INVOICE**

22963

**DATE**

3/7/22